

## Zirconia verses lithium disilicate restorations in different indications: A Clinical Case Series

Dr. Navanya.K<sup>1</sup>, Dr. Shashidhara.H.S.<sup>2</sup>

<sup>1</sup>(P.G. Student, Department Of Prosthodontics, College Of Dental Sciences, Davangere, India)

<sup>2</sup>(Professor, Department Of Prosthodontics, College Of Dental Sciences, Davangere, India)

---

**Abstract :** The full coverage, all-ceramic restoration of an anterior tooth and a posterior tooth with masticatory forces is a challenging clinical situation for which a variety of all-ceramic systems are available. The decision making process involves the consideration of a number of factors such as underlying substrate colour, tooth preparation geometry, margin location and cementation system. The increase in patient demands for enhanced esthetics has prompted the development of several all-ceramic restorative systems. This material appears to have adequate strength and toughness to allow for the fabrication of anterior and posterior crowns and fixed partial dentures. This case series describes four clinical cases involving different indications to illustrate the use of two different ceramic material used for patients with aesthetic problems related to enamel defects, diastema, spacing by lithium disilicate, known by their trade name emax and restoration of an endodontically treated maxillary premolar with the zirconia-based Lava system. Two of the most popular all ceramic systems zirconia-based or lithium disilicate-based restoration enables a prosthodontist to restore almost all indication in fixed prosthodontics and achieve the same aesthetic result. All-ceramic systems have expanded the range of restorative treatment options significantly and at the same time have simplified the handling of the material.

**Keywords -** Aesthetic restorations, all ceramic, alumina or zirconium oxide, lithium disilicate glass-ceramic, monolithic crowns.

---

### I. INTRODUCTION

The Lithium disilicate is emerging as a restorative material of choice for single unit indirect restorations. Lithium disilicate is a “monolithic” glass ceramic restoration. It offers dentists improved fit, improved esthetics, and improved durability. Metal, zirconia, resin, and conventional feldspathic porcelain still have an important role, but emax is perhaps the most versatile and chip resistant option available. It can be “pressed” or milled using a CAD/CAM system into full contour. It has no interface, and no layered veneer. They are customized with paint-on shades and then a layer of glaze for a final shine.

Full Contour Zirconia is exactly what it says, a crown made to full contour of solid zirconia. Although much less esthetic than emax, it is far stronger and therefore well suited to withstand severe parafunctional activity. Full contour zirconia is surprisingly popular also. It is not the most esthetic option but it is very strong, and so a great choice for posterior teeth.

Metal-free restorations have a strong ceramic core onto which layering ceramic is applied to achieve a natural appearance. These all-ceramic systems can be categorized broadly into two groups, based on the ceramic core they have.

- I. Translucent core, For example, Leucite Core - IPS Empress Esthetic ,Lithium disilicate Core – IPS emax
- II. Opaque core; For example, Lithium disilicate Core – IPS emax, Alumina core –In ceram Alumina, Procera, AllCeram , Zirconica core – Lava, Cercon, Procera Zirconia, Cerona.

The All-ceramic crowns with translucent core are superior in aesthetics, but weaker in strength. These crowns can be used to cover acceptably colored dentin and at times for rehabilitation of anterior teeth, where the masticatory load is less. Crowns with an opaque core are indicated for teeth with heavily discolored dentin or over metal posts and can be used for posterior crowns and some can be used for posterior FPD as they have superior strength. In this case series four cases ranging from placement of single crown restorations to aesthetic rehabilitation are illustrated with the meticulous selection of the type of material used to achieve successful outcomes with all-ceramic restorations. Close collaboration between the patient, dentist and laboratory technician is paramount to define and achieve the treatment goals.

## **II. Case Presentation**

### **2.1) CASE-I: ALL CERAMIC AESTHETIC CORRECTION FOR A CASE OF ORTHODONTIC RELAPSE (Fig.1)**

A 28-year-old female patient reported to the department with a chief complaint of spacing in the upper front teeth region since one year with a history of orthodontic treatment 7 years back. On intraoral examination it was observed that there was a lingual retainer cemented on to the palatal and lingual surface of the maxillary and mandibular anterior region respectively. History of broken lingual retainer in the maxillary arch 3 years back would have been the cause of occurrence of spaces between the teeth. Spacing between teeth w.r.t. 11,12,13,21 were observed.

Treatments were planned for the case of orthodontic relapse and for the failed retainer and the patient was given an option of orthodontic treatment, as the patient desired an immediate permanent long lasting restoration, all ceramic lithium disilicate laminates were planned for the aesthetic rehabilitation of the maxillary anterior region. A study wax-up was created to know the proportionate of the laminates for the aesthetic closure of the spacing, meanwhile maintaining a pleasing smile. It was also planned for minimal preparation for laminate with no incisal overlapping w.r.t. 13 and as the cusp tip was attrited w.r.t. 11, 12, 21, laminates were planned involving the incisal edges, of which both were considered a conservative option. The diagnostic template which had been created on the basis of the wax-up, served as a guide for preparation of the teeth. Smile was analyzed with the provisional restorations. And after the esthetic satisfaction of the patient the four laminates were cemented.

### **2.2) CASE-II: REHABILITATION OF THE HYPOCALCIFIED TEETH WITH MONOLITHIC CROWN (Fig.2)**

A 30- year-old man reported to the department with the general defects of the tooth structure. The patient requested to have the brightness value of his teeth improved permanently and to undergo aesthetic reconstruction to improve the morphology and function of his teeth. After conducting an intraoral examination and obtaining a medical history, it was diagnosed as a case of enamel hypoplasia with a history of calcium deficiency during the childhood.

Intra oral examination revealed generalized brownish discoloration of the teeth involving multiple teeth with rough and pitted surface of anterior and posterior teeth of different severity. Patient had full metal crown on one of the posterior tooth. From the patient's point of view for correction of the esthetic of only the visible tooth, it was decided for lithium disilicate crowns w.r.t. 11 and 12 which was severely discolored and which was of aesthetic concern of the patient. Hence the hypo-calcified discolored crown was restored with lithium disilicate crown with minimal tooth preparation.

### **2.3) CASE-III: ALL CERAMIC CROWNS MAINTAINING AN ORIGINAL SMILE WITH MIDLINE DIASTEMA (Fig.3)**

A 24-year-old man reported to the department with a chief complaint of dislodged crowns in the upper tooth region. On intraoral examination it was observed, root canal treated teeth w.r.t. 11 and 21 with dislodged porcelain fused to metal crown and the mesiodistal distance between 11 and 21 was more with midline diastema and a generalized spacing in the maxillary anterior region was present. The previous crowns w.r.t. 11 and 21 was wide covering the midline diastema.

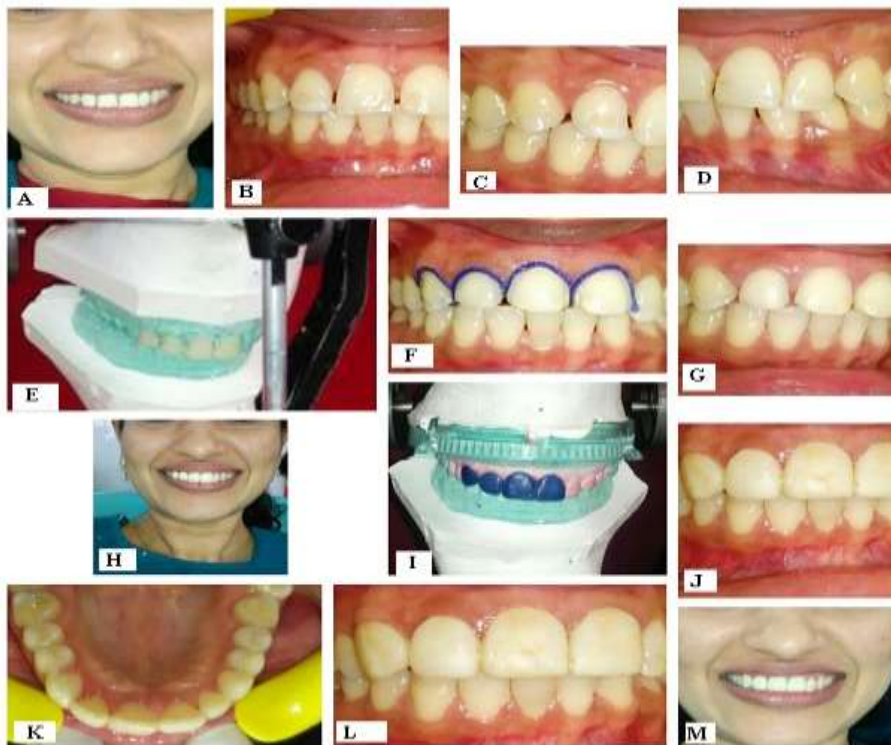After the patient's concern, it was decided to restore the teeth with lithium disilicate by maintaining the midline diastema. The patient's aesthetic expectations were satisfied completely with reconstruction of the teeth.

### **2.4) CASE-IV: AESTHETIC EFFICIENCY WITH AN ALL CERAMIC ZIRCONIA CROWN IN AN ENDODONTICALLY TREATED TOOTH (Fig.4)**

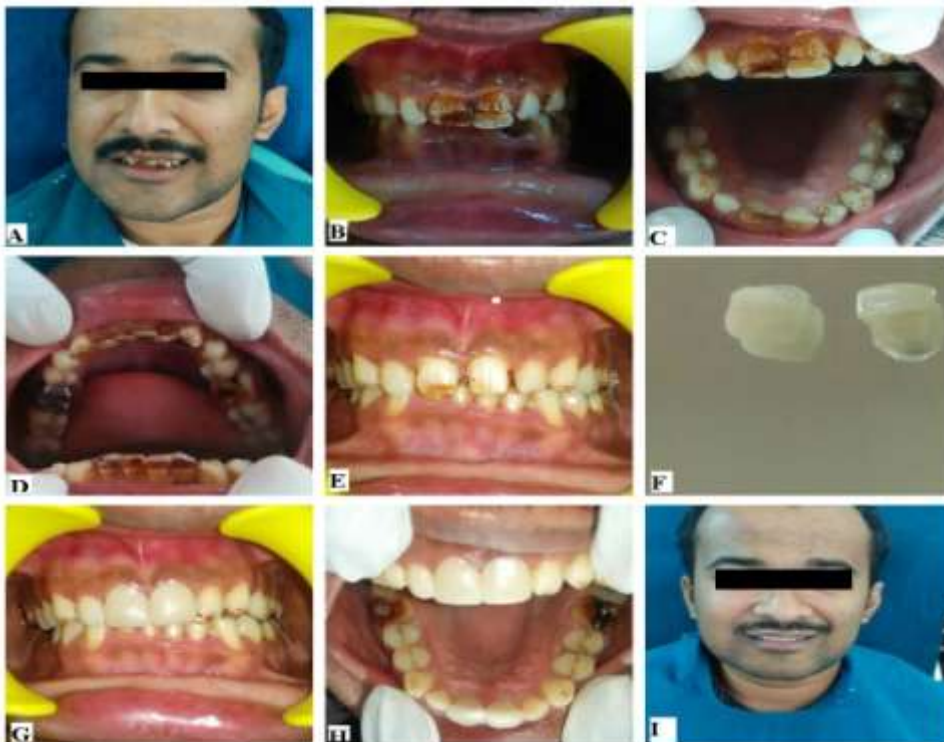A 35 year-old-female came to the department with the dislodged maxillary posterior crown. On intraoral examination, tooth w.r.t. 15 was a root canal treated with previous porcelain fused to metal dislodged crown and on examination, there was insufficient coronal structure which would have been the cause for the dislodgement. Henceforth from the patient's point of view in need for the retentive and aesthetic restoration, it was decided for the crown lengthening of the tooth w.r.t. 15 followed by fibre post and core build which was followed by all ceramic zirconia full crown.

The objective of a post-and-core buildup is primarily to replace missing coronal tooth structure sufficiently to provide adequate retention and resistance for the crown followed by zirconia crown which as a strong material compared to lithium disilicate would eventually restore the function and the aesthetics of the tooth in question.

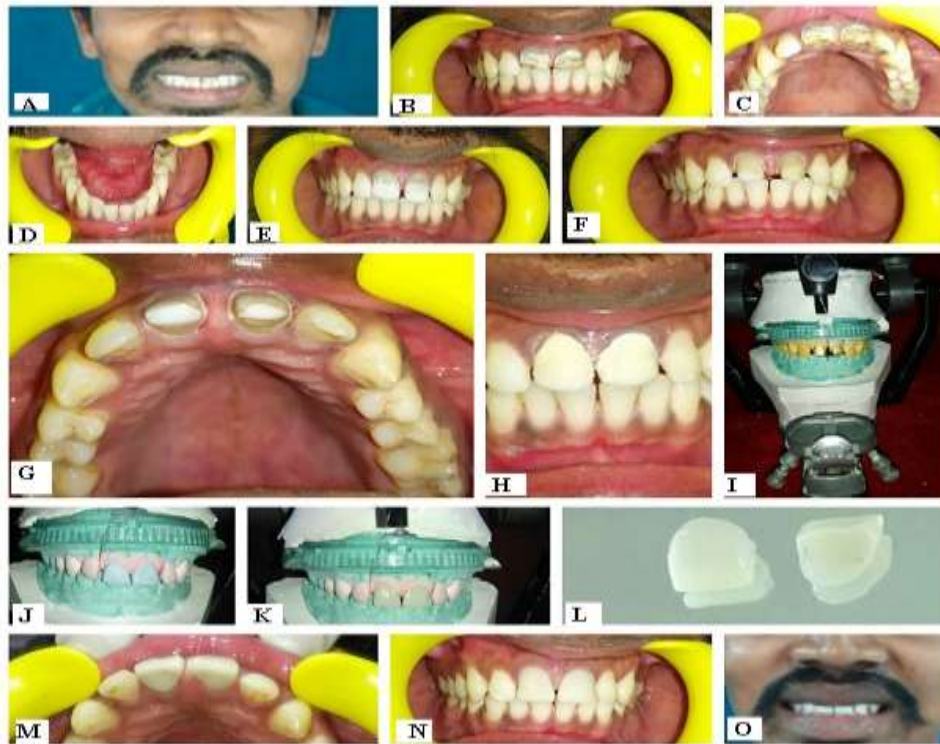III.FIGURES



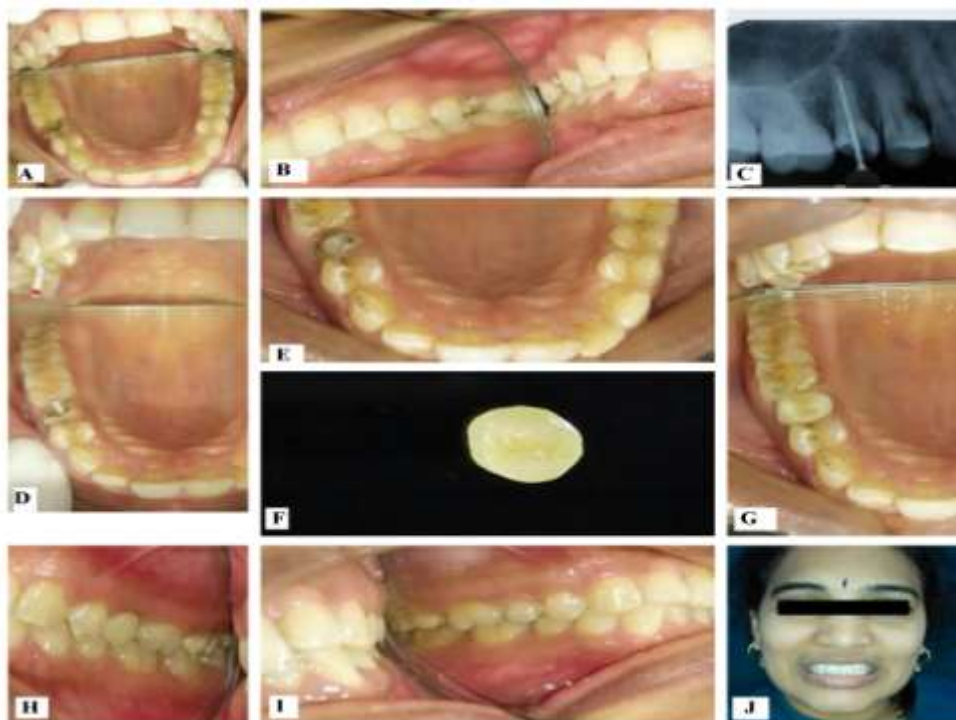
**Figure 1** – A) Preoperative extraoral frontal view, B) Preoperative intraoral frontal view, C) Preoperative intraoral right lateral view, D) Preoperative intraoral left lateral view, E) Mock up on cast, F) Tooth preparation and gingival retraction, G) Chamfer finish line w.r.t. 11,12,13,21 H) Temporization, I) Wax pattern, J) Postoperative intraoral frontal view, K) Postoperative intraoral maxillary occlusal view, L) Postoperative intraoral right lateral view, M) Postoperative extraoral frontal view.



**Figure 2** – A) Preoperative extra oral frontal view with intrinsic stains, B) Preoperative intraoral frontal view, C) Preoperative intraoral maxillary occlusal view, D) Intraoral mandibular occlusal view, E) Tooth preparation of 11, 21, F) emax crowns, G) Postoperative intraoral frontal view, H) Postoperative intraoral maxillary occlusal view, I) Postoperative extraoral frontal view.



**Figure 3** – A) Preoperative extraoral frontal view, B) Preoperative intraoral frontal view after the dislodged PFM crown, C) Preoperative intraoral maxillary occlusal view, D) Intraoral mandibular occlusal view, E) Core buildup of 11,21, F) Tooth preparation with shoulder finish line of 11,21, G) Tooth preparation-maxillary occlusal view, H) Temporization, I) Cast with die cutting of 11,21, J) Wax pattern fabrication, K) emax crowns on the cast, L) emax crowns stained and glazed, M) Postoperative intraoral maxillary occlusal view, N) Postoperative intraoral frontal view, O) Postoperative extraoral frontal view.



**Figure 4** – A) Preoperative intra oral maxillary occlusal view with loss of distobuccal tooth structure, B) Preoperative intraoral right lateral occlusal view with reduced occluso-cervical height of tooth structure, C) Post preparation leaving 4mm of gutta-percha at the apex, D) Checking the fit of the fibre post, E) Core build,

F) Zirconia crown, G ) Postoperative intraoral maxillary occlusal view, H) Postoperative intraoral right lateral occlusal view, I) Intraoral left lateral occlusal view, J) Postoperative extraoral frontal view

#### **IV. Discussion**

Maxillary anterior teeth malformation such as enamel hypocalcification, midline diastema, spacing between the teeth can present aesthetic problems. Such situations also can demand an efficient treatment.

There are numerous all-ceramic systems available on the market, and two of the most popular systems are zirconia-based or lithium disilicate-based. The question becomes, which system should be chosen and when? Strength and longevity become important parameters when making the choice. Lithium disilicate crowns are monolithic. Zirconia-based crowns are veneered with a relatively weak ceramic material. Because of this fundamental difference in composition, the behavior of use of all silica/glass-based all-ceramic crowns in combination with resin cements has the potential to provide a more aesthetic solution than conventional ceramometal crowns. However, correct use of these materials is extremely technique-sensitive. They require additional marginal precision of the tooth preparation and they need to be bonded with resin cements. As such correct case selection, tooth preparation and bonding protocol are essential for long term success.

An area where the zirconia-based and lithium disilicate crowns differ substantially is translucency. Different zirconia materials possess different levels of translucency; nevertheless, because of its higher crystalline content, it is considerably less translucent when compared with lithium disilicate. When of equal thicknesses, the most translucent zirconia is only 73% as translucent as conventional lithium disilicate. Higher translucency will let more light into the restoration, and if used in conjunction with clear cement, a more life-like appearance can often be achieved. In this case series patient's aesthetic expectations were successfully met through selection of lithium disilicate crowns for anterior restoration and zirconia oxide restoration for posterior tooth.

#### **V. CONCLUSION**

Since the advent of the aesthetic improvement in all ceramic, full zirconia crown are recommended for premolar, molar teeth, and lithium disilicate for anterior teeth. Lithium disilicate will continue to be the major aesthetic material for single crowns, onlays, veneers, and inlays for the short-term future. Lithium disilicate glass-ceramic full crowns have demonstrated satisfactory in the anterior aspect, as well as in the load bearing zone. There is also the question of the type of restoration—single crown versus fixed partial denture (FPD), anterior restoration versus posterior restoration. Zirconia is a very strong material that can support the heavy masticatory force for posterior teeth and lithium disilicate for anterior teeth.

#### **REFERENCES**

- [1]. Succaria F, Morgano SM. Prescribing a dental ceramic material: Zirconia vs lithium-disilicate. *Saudi Dent J*. 2011 Oct;23(4):165-6.
- [2]. Edelhoff D, Brix O. All-ceramic restorations in different indications: a case series. *J Am Dent Assoc*. 2011 Apr;142 Suppl 2:14S-9S.
- [3]. Ritter RG. Multifunctional uses of a novel ceramic-lithium disilicate. *J Esthet Restor Dent*. 2010 Oct;22(5):332-41.
- [4]. Mizrahi B. All-ceramic silica/glass-based crowns—clinical protocols. *Br Dent J*. 2011 Sep 23;211(6):257-62.
- [5]. Yu J, Yang Y, Gao J, Guo J, Li L, Zhao Y, Zhang S. Clinical outcomes of different types of tooth-supported bilayer lithium disilicate all-ceramic restorations after functioning up to 5 years: a retrospective study. *J Dent*. 2016 Jun 1.